

---

# Early Clinical Experience with the Cochlear™ Nucleus® SmartNav System: Real-time Surgical Insights

David Kelsall, M.D. and J. Eric Lupo, M.D., M.S.  
Rocky Mountain Ear Center  
Englewood, CO, USA

---

## Introduction

The Cochlear™ Nucleus® SmartNav System provides real-time intraoperative measurements offering the surgeon confidence about the placement and function of the electrode array in the cochlea. Cochlear implant intraoperative testing is important because it can provide clinical insights during and after the procedure to assist and reassure the surgeon and audiological team in their goal to optimize hearing outcomes for CI recipients and their families.

Cochlear's new intraoperative system gives real-time feedback during surgery to provide surgeons key insights when making important decisions. The system features include real-time insertion speed, angular insertion depth, as well as a final electrode array placement analysis and summary. The electrode array placement analysis, enabled for all Cochlear electrodes, except Hybrid, provides useful and potentially actionable information about any electrode position issues, such as a tip fold over or kink. This information allows the surgeon to act directly in the OR when necessary, and potentially avoid intraoperative imaging or future revision surgery. While the measurements of speed of insertion and placement check can be utilized with all of our electrodes, the angular insertion depth measurement is only enabled for straight electrodes" (Cochlear Nucleus CI622, CI624, CI522, and CI422 cochlear implants). The SmartNav app includes the ability to take electrode impedance and AutoNRT® measurements to confirm device functionality prior to leaving the OR and support initial device activation.

## Background

Intraoperative testing can provide valuable information to confirm device function, electrode array position, and electrode placement anomalies, consequently reducing the need to return to the operating room (OR) for revision surgery or intraoperative imaging (Page et al., 2017; 2018). Intraoperative electrophysiological assessment can help audiologists during initial device programming, especially with very young children or less cooperative individuals (Page et al., 2017; 2018).

Confirmation of electrode placement is routinely performed with intraoperative imaging, such as plain skull film or fluoroscopy. This confirmation may be recommended by device manufacturers. Unfortunately, this imaging capability may not always be available. It is also important to reduce or avoid the consequences of radiation exposure from intraoperative and postoperative x-rays when possible (Copeland, et al., 2004). For the best possible hearing outcomes, it is essential to minimize intracochlear damage and preserve cochlear health during surgery as much as possible. Keeping the electrode array completely within the scala tympani, and addressing resolvable electrode placement anomalies, albeit infrequent, such as tip fold over (< 5% of insertions) and incomplete electrode insertion (< 2% of insertions) (Ishiyama et al., 2020) may help improve surgical outcomes. A relatively slow and consistent insertion speed of the electrode into the cochlea may help improve surgical outcomes by preserving intracochlear structures. (Rajan et al. 2013)

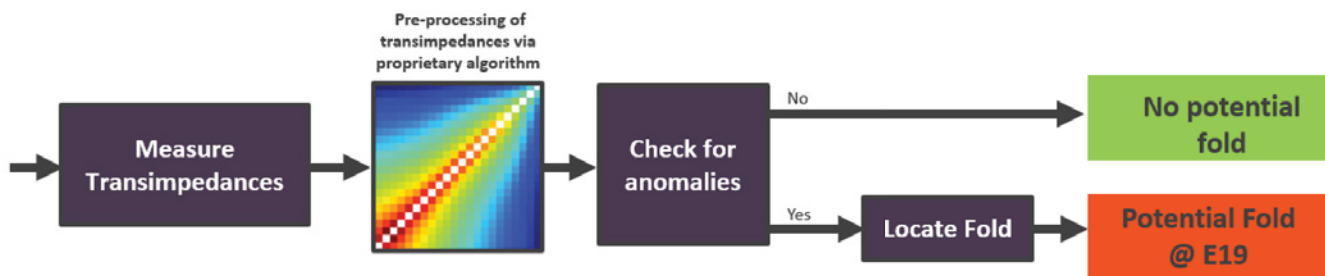
Based on the Rocky Mountain Ear Center’s (RMEC) experience using the SmartNav system in 116 cochlear implant ears/surgeries, the goal of this report is to describe our experiences to help guide others. We also compare our experiences to using traditional intraoperative fluoroscopy. We conclude with clinical recommendations for surgeons who may consider including this system into their clinical routine to further verify surgical outcomes.

### How does the SmartNav system work?

The SmartNav system requires a compatible iPad wirelessly paired to a CP1150S surgical processor. In order to collect real-time angular insertion depth and insertion speed measurements, SmartNav must be set up and the surgical processor paired with the cochlear implant prior to electrode insertion. In addition, the extracochlear ground electrodes, MP1 and MP2, must be in contact with tissue so that a current path exists between the intra- and extracochlear electrodes during the insertion. Specifically, the extracochlear electrode MP1 must be under the temporalis muscle and the skin flap must be placed over the implant’s plate electrode MP2 prior

to beginning these measurements. It is important that the tissue/plate electrode interface is wet, and that contact is good to ensure a stable current path during measurements. When collecting only post electrode insertion measurements, i.e., Placement Check, impedances and AutoNRT measurements, ensure both extracochlear electrodes are placed correctly, as noted above, prior to collecting data. In the software, electrodes with impedances in the normal range are highlighted in green and electrodes that are short or open circuit are highlighted in red. Placement Check identifies where two or more electrodes may be placed incorrectly and could represent a fold; these electrodes are highlighted in red.

### The Nucleus SmartNav system placement check background

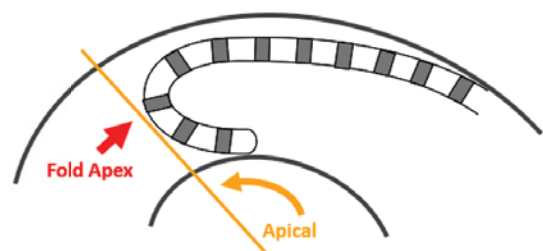


#### Definition of fold

Reversal in angular position at the apical end of the electrode array

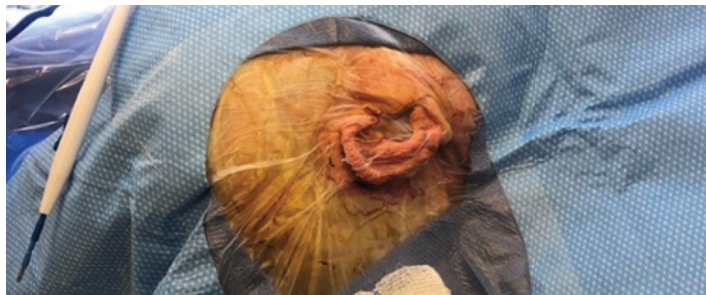#### Criterion for significance

Placement check will detect folds where the most apical point of the array is E20 or less (i.e., two or more electrodes folded)



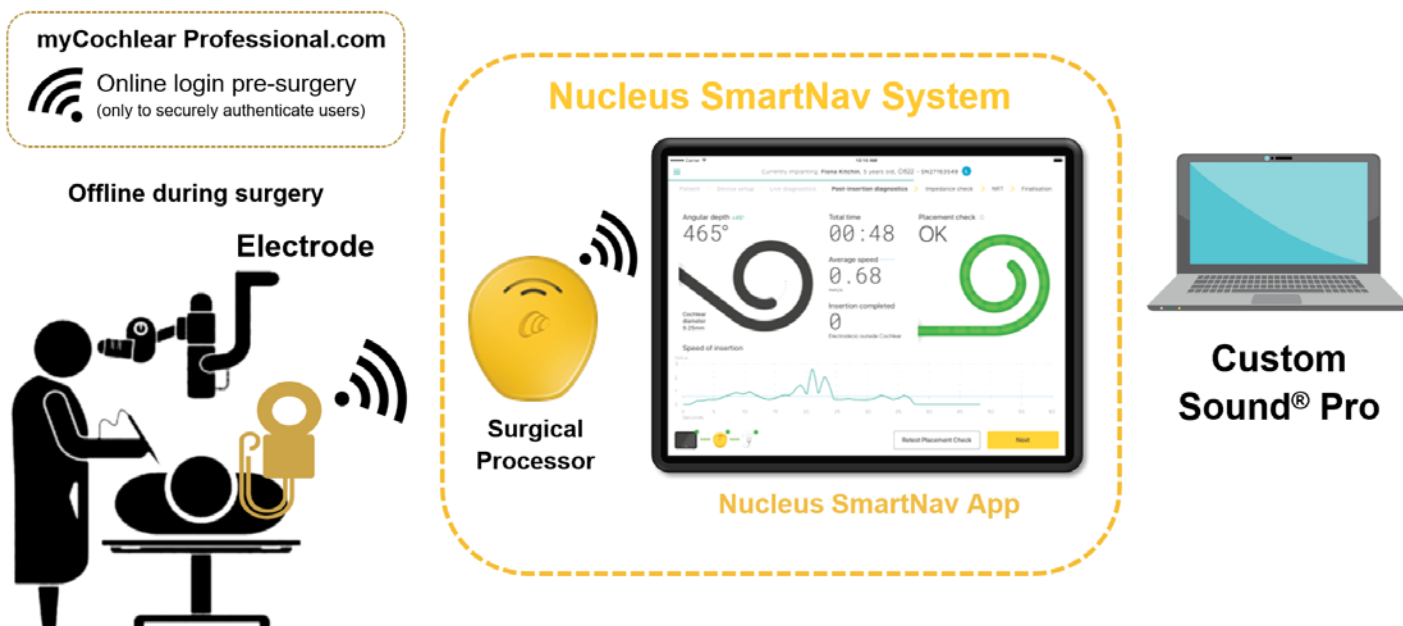
## SmartNav surgical workflow

**OR Set Up:** 1) Soft tissue thickness measurement at anticipated site of antenna/receiver, 2) Surgical draping prepared over patient, 3) Audiologist/operator logs into SmartNav, 4) Patient profile generated 5) Cochlear diameter is entered, if diameter is unknown, allow system to use default measurement, 6) Implant barcode scanned, 7) Test connection to surgical processor.



Example of draping from RMEC- ample thin draping for secure connection from implant to surgical processor

## Nucleus SmartNav Ecosystem



**Surgery Begins:** 1) Audiologist/operator prepares SmartNav to begin, 2) Processor placed in sterile bag and handed to surgical field, 3) Audiologist communicates with surgeon's readiness to begin.

**Electrode Insertion:** 1) Prior to electrode insertion, surgeon seats implant in pocket under skin flap ensuring contact of the MP2 plate electrode, 2) MP1 ground electrode is inserted under the temporalis muscle and surgeon places processor on top of implant antenna/receiver location, 3) Audiologist/operator connects iPad/processor/implant, 4) Audiologist/operator indicates readiness to proceed, 5) Surgeon indicates start Live Diagnostics (angular insertion depth {straight arrays only} and insertion speed), and when to stop after electrode insertion.

**Post Insertion:** 1) Audiologist/operator runs post insertion diagnostics (Placement Check, impedances, and AutoNRT). The post insertion summary provides information about the final angular insertion depth in degrees, insertion speed, including average speed and total time, number of extracochlear electrodes, and a Placement Check to confirm correct array placement or identify the possibility of an electrode tip fold over, including the range of electrode contacts involved.

---

## The experience

The Rocky Mountain Ear Center was invited to participate in a controlled market release (CMR) using the SmartNav system during routine cochlear implant surgery and to provide feedback via surveys prepared in collaboration with Cochlear Americas. RMEC took part in the SmartNav CMR, and two surgeons recorded their experiences during surgery, for a total of 116 CI recipients consecutively implanted with the *Cochlear Nucleus® Profile Plus with the Slim Modiolar Electrode (CI632) cochlear implant*.

Slim perimodiolar arrays have been designed to help preserve intracochlear structures and aid in maintaining a healthy cochlear environment, in addition to enabling focused neural stimulation (Long et al., 2014; Davis et al, 2016; Gibson and Boyd, 2016). Research has shown a positive correlation between speech perception scores and electrode array position closer to the modiolar wall, e.g., perimodiolar placement, and a higher number of

---

## Results

Our clinic performed SmartNav measurements over a 12-month period in N = 113 patients and in 116 implanted ears. Table 1 shows demographics for the N = 113 patients. Table 2 provides the results obtained via SmartNav for 116 ears.

electrode contacts within the scala tympani (Holden et al., 2013). Furthermore, a greater number of stimulating electrode channels and a smaller distance between the electrodes and modiolar can positively influence speech recognition outcomes compared to electrode positioning along the lateral wall (Croghan et al., 2017; Berg et al., 2019; Holder et al., 2019).

All SmartNav measurement features were attempted intraoperatively with 113 patients. During electrode insertion, real-time insertion speed was measured. Post insertion diagnostics including an implant Placement Check, total time and average speed of electrode insertion, and number of extracochlear electrodes, were completed. Prior to the patient leaving the OR, an intraoperative fluoroscopy image, based on the standardized protocol described in Cooper et al., 2019, was taken to ensure placement of the electrode array and identify addressable issues, such as tip fold over. This radiologic image and SmartNav results were compared.

---

Table 1. Patient Demographics, N=113 patients, 116 ears

| Variable                              | Number (%)               |
|---------------------------------------|--------------------------|
| <b>Age mean (range)</b>               | 60.5 years<br>(0.9 – 93) |
| <b>Gender</b>                         |                          |
| Male                                  | 58 (51%)                 |
| Female                                | 55 (49%)                 |
| <b>Surgical Approach (N=116 ears)</b> |                          |
| Round Window                          | 62 (53%)                 |
| Extended Round Window                 | 44 (38%)                 |
| Cochleostomy                          | 10 (9%)                  |
| <b>Implants per patient</b>           |                          |
| Unilateral                            | 110 (97%)                |
| Bilateral                             | 3 (3%)                   |

---

Table 2. Summary of SmartNav Results, 116 ears

| SmartNav Measurement                    | Proportion of ears (%)      |
|---|-----------------------------|
| <b>Placement check</b>                  |                             |
| <b>Obtained measurement</b>             | <b>109/116 ears (94%)</b>   |
| Green                                   | 92/109 ears (84%)           |
| Green with some external electrodes     | 15/109 ears (14%)           |
| Red indicating TFO (electrodes 22 - 20) | 2/109 ears (2%)             |
| Time (seconds) Mean, (range)            | 121 secs (66-254)           |
| <b>Impedance Measurements</b>           |                             |
| Obtained Measurement                    | 115/116 ears (99%)          |
| All 22 electrodes Green                 | 104/115 ears (90%)          |
| 1, 2 or 3 open circuits (red)           | 11/115 ears (10%)           |
| Time (seconds) Mean                     | 31 secs                     |
| <b>NRT Measurements</b>                 |                             |
| Obtained Measurement                    | 113/116 ears (97%)          |
| NRT obtained on 2 or more electrodes    | 113/116 ears (97%)          |
| Time (minutes) Mean, SD, (range)        | 2.99 SD. 0.96 (0.27 - 7.28) |

## Electrode placement check

Placement Check was performed in 94% (109/116) ears. In four ears, the measurement was attempted and could not be conducted due to Radio Frequency (RF) link intermittencies. In three of these, the skin flap thickness was 7mm or more and in one case the skin flap was not measured. In addition, placement check was skipped in two cases with skin flaps of 5mm or less and no evidence of intermittency. Finally, in one case with a skin flap of 5mm, placement check could not be conducted because the two extracochlear electrodes were not placed and in contact with tissue.

## Objective electrophysiological measures

Impedance and AutoNRT measurements were carried out in all surgeries. Impedance measurements were successfully obtained in 99% (115/116) ears, and NRT measurements were successful in all but three ears. In two cases, NRT was not obtained due an intermittent RF signal; in the third case, NRT responses were not obtained on any of the electrodes tested. The average time to obtain NRT measurements was 2.99 min (SD 0.96; range 0.27 -7.28). The average measurement time for measuring impedances and conducting NRT on the full array was 3 mins 30 secs (D. Kelsall, MD, personal communication). This compares to an average measurement time of 2 mins 25 secs for impedance checks and sampling of 9 electrodes for NRT using the Cochlear™ Nucleus® CR220 Intraoperative Remote Assistant (RMEC unpublished data from N = 50 patients).

## SmartNav versus fluoroscopy outcomes

In N = 116 ears/surgeries, intraoperative fluoroscopy was obtained and interpreted by the operating surgeon and radiologist. There were two cases of tip fold over based on intraoperative imaging. SmartNav’s Placement Check confirmed tip fold over in both of these cases resulting in 100% accuracy in detection of tip fold over intraoperatively via SmartNav compared to imaging. In both cases, the electrode array was withdrawn, reloaded and successfully reinserted resolving the issue prior to leaving the OR. In a third case, for whom Placement Check could not be completed due to RF intermittency, intraoperative imaging revealed a tip fold over. Resolution in this case involved a replacement device before leaving the Operating room.

*To illustrate our experience with SmartNav further we will describe two case studies.*



---

### Case study 1

83yrs of age, male, underwent routine cochlear implantation. Following an inadvertent movement of the stabilized electrode array sheath, resistance was met on further insertion of CI632 implant. SmartNav placement check was run immediately and indicated tip fold over which was suspected based on insertion resistance. The electrode was carefully withdrawn and reloaded and reinserted. Follow up placement check by SmartNav indicated good placement with no tip rollover. Subsequent x-ray confirmed placement and patient has done well postoperatively. His CNC word score improved from 8% before implant to 48% at 6 months post implant and patient is satisfied with outcome obtained through CI.

### Case study 2

85yrs of age, male, presented for evaluation of poor performance on 2nd side CI performed at an outside clinic. Patient had been implanted unilaterally on left 9yrs prior and had done well with bimodal hearing (CI + HA) until 2019. He had been having increasing difficulty with traditional amplification on the right ear. He received right CI in 2019. Patient had poor performance from the start of activation with a score of 16% CNC words in quiet for the right ear. CT had been obtained and initially read as normal, however, on close inspection, an apical tip fold over was appreciated. Patient was counselled for revision CI surgery, and he elected to proceed. At surgery, once patient was prepped, SmartNav placement check was run indicating tip fold over. The prior implant was removed and replaced without difficulty using a CI612 device. SmartNav placement check was run indicating good placement. An intraoperative x-ray was obtained demonstrating no tip fold over. Post operatively patient scores improved to 64% on CNC words in quiet at 6 months post implantation and patient is satisfied with his hearing performance with bilateral implantation.

These cases highlight how using SmartNav enabled timely detection and efficient resolution of issues by the surgeon, during an original procedure and in revision surgery, prior to patients leaving the OR.

---

## Discussion

RMEC successfully completed all SmartNav tests in > 94% of ears. A stable RF link is necessary to complete testing. In our cohort, the average scalp thickness was 5.5mm (SD1.5; range: 3-14mm). Published research has shown that skin flap thickness over the temporo-parietal area, when measured in 236 adult non-CI patients under general anesthesia, showed a significant inverse correlation with increasing age, ranging from an average of 8mm in younger adults (3rd decade) and reducing to 5mm in older adults (9th decade) (Ungar et al., 2018). This is consistent with skin flap thickness in adult CI-recipients typically seen in our clinic. We observed that when skin flaps were thicker than 7mm, there was an increased likelihood to experience an unstable RF link connection than for thinner skin flaps. Consequently, our early experience has shown the importance of using relatively thin draping methods in the surgical field in order to increase the likelihood of obtaining a consistently stable RF signal for successful measurements.

Intraoperative testing via SmartNav can offer additional confidence to the surgical team that the implant is functioning correctly, and that the electrode array is inserted and placed as desired before leaving the OR. This can avoid the additional time, resources and cost of a return to the OR in the event the array placement is identified as not ideal after surgery. These benefits can be seen through the experience in our clinic and specifically benefits can be seen in the detailed cases presented.

Currently, across US centers, intraoperative implant testing is generally performed. This extra step increases OR time, equipment and staff resources, especially among audiological staff. Although many surgeons perform some amount of intraoperative testing, it appears that the test results affect surgical decisions or patient management infrequently (Page et al., 2017; 2018). Surgically it is important to maximize the efficiency of any time spent in testing to monitor the surgical outcomes. Our surgical experience with SmartNav indicates actionable data can be derived to help ensure electrode function upon exit from OR.

---

## Clinical recommendations

Based on our experience we offer the following guidance to surgeons considering the use of SmartNav:

- SmartNav is an easy to use, efficient, automated option to consider, confirming electrode array placement when intraoperative imaging is not available or not desired

### Using SmartNav is a change to the current surgical procedures and requires training:

- OR staff must be trained on the correct sequence of steps to ensure successful real-time measurements

### Prior to electrode insertion, it is essential that:

- the surgical processor is paired with the cochlear implant
- both extracochlear ground electrodes are in contact with tissue to ensure a current path between the intra- and extra-cochlear electrodes during electrode array insertion

### Ongoing communication between the surgeon and iPad operator (e.g. audiologist) includes:

- feedback from the operator that the surgical processor is receiving an RF signal and the stability of the RF link throughout measurements
- instruction from the surgeon when to start and stop the live diagnostics to ensure accuracy of measurements

### Draping considerations for RF link stability:

- thin draping will maximize the likelihood of a stable RF connection between the surgical processor and implant
- thick draping can lead to possible RF intermittencies
- skin flaps > 7mm may have a higher likelihood of RF intermittencies
- applying manual pressure may overcome RF intermittencies when noted in some cases

## Conclusions

Our experience with a relatively large cohort implanted with a slim perimodiolar electrode array has shown that SmartNav has an intuitive workflow and can provide surgeons with real-time feedback during electrode array insertion. This information can provide additional confidence to the surgeon about surgical outcomes and further support decision

making in the OR. SmartNav provides an efficient and accurate method to measure impedances and AutoNRT, giving added assurance the implant is placed and operating as intended.

Placement Check provides valuable information on final electrode placement that can potentially reduce the need for intraoperative imaging and/or lead to resolution before leaving the OR. In our opinion, given the accuracy of Placement Check which was performed in 94% (109/116) ears, SmartNav can be used as the primary tool for electrode array placement confirmation, including to rule out tip fold over. In cases where SmartNav detects an aberration, intraoperative imaging can be used as an additional method of confirmation.

In our experience we observed that SmartNav:

- has a simple user interface and is easy to use
- improves OR efficiency and supports surgical decision making
- increases confidence that the implant is placed correctly
- Placement Check algorithm was 100% accurate and specific in the detection of tip fold overs as confirmed by intraoperative imaging
- can save time and reduce radiation exposure from x-rays before and after leaving the OR
- has the potential to be routinely used to confirm electrode placement before leaving the OR, especially in clinics that are without intraoperative imaging capabilities.

Additional efforts to learn about outcomes when using SmartNav in a wide range of patient profiles across a range of implant clinics, may help further build upon the current knowledge and level of confidence in its use and benefits in routine clinical practice.

## Acknowledgements

We would like to thank our collaborating OR staff and our patients for enabling us to use SmartNav in the realm of our daily clinical practice and subsequently share our experiences in this report.

## References

1. Berg KA, Noble JH, Dawant BM, Dwyer RT, Labadie RF, Gifford RH. Speech recognition as a function of the number of channels perimodiolar electrode. *J Acoust Soc Am*. 2019; 145:1556-1564.
2. Cooper T, Hildrew H, McAfee JS, Piatt BK, Branstetter IV B, et al. Optimization of intraoperative imaging protocol to confirm placement of cochlear implant electrodes. *Otol Neurotol*. 2019; 40:625-629.
3. Copeland BJ, Pillsbury HC, Buchman CA. Prospective evaluation of intraoperative cochlear implant radiographs. *Otol Neurotol*. 2004; 25:295-297.
4. Croghan NBH, Duran SI, Smith ZJ. Re-examining the relationship between number of cochlear implant channels and maximal speech intelligibility. *J Acoust Soc Am*. 2017; 142:537-543.
5. Davis TJ, Zhang D, Gifford RH, Dawant BW, Labadie RF, Noble JH. Relationship between electrode-to-modiolus distance and current levels for adults with cochlear implants. *Otol Neurotol*. 2016; 37:31-37.
6. Gibson P, Boyd P. Optimal electrode design: Straight versus perimodiolar. *Eur Ann Otorhinolaryngol Head Neck Dis*. 2016;133:Suppl 1:S63-65.
7. Holden LK, Finley CC, Firszt JB, Holden TA, Brenner C, Pott LG, et al. Factors affecting open-set word recognition in adults. *Ear Hear*. 2013; 34:342-360.
8. Holder JT, Yawn RJ, Naissiri AM, Dwyer RT, Rivas A, Labadie RF, et al. Matched cohort comparison indicates superiority of precurved electrode arrays. *Otol Neurotol*. 2019; 40:1160-1166.
9. Ishiyama A, Risi F, Boyd P. Potential insertion complication with cochlear implant electrodes. *Cochlear Implants Int*. 2020; 21: 206-219.
10. Long, CJ, Holden TA, McClelland GH, Parkinson WS, Shelton C, Kelsall DC, et al. Examining the electro-neural interface of cochlear implant users using psychophysics, CT scans, and speech understanding. *JARO*. 2014; 15: 293-304.
11. Page JC, Murphy L, Kennett S, Trinidad A, Frank R, Cox M, et al. The influence of intraoperative testing on surgical decision-making during cochlear implantation. *Otol Neurotol* 2017;38:1092-1096.
12. Page JC, Cox MD, Hollowo B, Bonella-Velez J, Trinidad A, Dornhoffer JL. Trends in intraoperative testing during cochlear implantation. *Otol Neurotol*. 2018; 39:294-298.
13. Rajan GP, Kontorinis G, Kuthubutheen J. The effects of insertion speed on inner ear function during cochlear implantation: A comparison study. *Audiol Neurotol*. 2013;18:17-22. DOI: 10.1159/000342821.
14. Ungar OJ, Amit U, Cavel O, Oron Y, Handzel O. Age-dependent variations of scalp thickness in the area designated for a cochlear implant receiver stimulator. *Laryngoscope Investigative Otolaryngology*. 2018; 3:496 - 499.

This material is intended for health professionals. If you are a consumer, please seek advice from your health professional about treatments for hearing loss. Outcomes may vary, and your health professional will advise you about the factors which could affect your outcome. Always read the instructions for use. Not all products are available in all countries. Please contact your local Cochlear representative for product information.

Cochlear Sound Processors are compatible with Apple and Android devices. Cochlear Smart Apps are available on App Store and Google Play. For compatibility information visit [www.cochlear.com/compatibility](http://www.cochlear.com/compatibility).

©Cochlear Limited 2022. All rights reserved. Hear now. And always and other trademarks and registered trademarks are the property of Cochlear Limited or Cochlear Bone Anchored Solutions AB. The names of actual companies and products mentioned herein may be the trademarks of their respective owners.

**Cochlear Americas**  
10350 Park Meadows Drive  
Lone Tree, CO 80124 USA  
Telephone: 303 790 9010  
Support: 800 483 3123

**Cochlear Canada Inc.**  
2500-120 Adelaide Street West  
Toronto, ON M5H 1T1 Canada  
Support: 800 483 3123

[www.cochlear.com/us](http://www.cochlear.com/us)